

Incidence and significance of demonstrating the meniscomfemoral ligament on MRI

¹B Y LEE, MD, ¹W H JEE, MD, ²J M KIM, MD, ¹B S KIM, MD and ¹K H CHOI, MD

Departments of ¹Radiology and ²Orthopedic Surgery, The Catholic University of Korea, Kangnam St Mary's Hospital, 505 Banpo-Dong, Seocho-Ku, Seoul 137-040, Korea

Abstract. The aim was to evaluate how often MRI can detect the meniscomfemoral ligament and if there is any relationship with the presence of lateral meniscal tears. Sagittal and coronal MR images of 138 patients with arthroscopically proven meniscal tears were included in this study. MR images were retrospectively reviewed for the presence of a meniscomfemoral ligament and a lateral meniscal tear. The χ^2 test was used for statistical analysis. Either one or both meniscomfemoral ligaments were shown in 114 (83%) of 138 patients on MR images. In 61 cases with a lateral meniscal tear, the meniscomfemoral ligament was present in 82% (50/61) and absent in 18% (11/61). In 77 cases without lateral meniscal tear, the meniscomfemoral ligament was present in 83% (64/77) and absent in 17% (13/77). A significant correlation was not established between the meniscomfemoral ligament and lateral meniscal tear ($p=0.85$).

The meniscomfemoral ligament is considered to be a stabilizer of the posterior horn of the lateral meniscus [1]. We hypothesized that the absence of the meniscomfemoral ligament may increase the likelihood of a tear of the posterior horn of the lateral meniscus. The meniscomfemoral ligament is composed of the anterior branch, or ligament of Humphrey, and the posterior branch, or ligament of Wrisberg. It has been identified on MRI in 30–94% of patients in previous studies [2–5].

The purpose of this study was to evaluate how often MRI can detect the meniscomfemoral ligament and if its presence has any relationship with the presence of lateral meniscal tears.

Materials and methods

138 patients (70 men and 68 women; aged 15–75 years, mean 38 years) with arthroscopically proven meniscal tears were included in this study. 77 patients had medial meniscal tears and 61 patients had lateral meniscal tears. We retrospectively reviewed MR images for the presence and absence of the meniscomfemoral ligament as well as a lateral meniscal tear. The meniscomfemoral ligament on MR images was defined as follows. (1) The ligament of Wrisberg or the ligament of Humphrey as a separate, ovoid hypointense focus or discrete hypointense bulge or lump, greater than 3 mm in thickness, immediately posterior or anterior to the posterior cruciate ligament, respectively, on sagittal images.

(2) A greater than 3 mm thick, low signal intensity band coursing obliquely from the posterior lateral meniscus to the medial femoral condyle on coronal images.

All MR images were obtained with a 1.5 T system (Signa; General Electric, Milwaukee, USA) and a transmit–receive extremity coil (General Electric Medical System). All patients were imaged in the supine position with the knees fully extended. T_1 weighted MR images (TR/TE 400–750/17–30 ms) were obtained in all patients. In 26 patients, conventional spin echo proton density weighted MR images (TR/TE 1800–3500/19–40 ms) and T_2 weighted MR images (TR/TE 1800–3500/60–100 ms) were obtained. In 112 patients, a fast spin echo pulse sequence was used to obtain proton density weighted MR images (TR/TE 1800–3500/19–40 ms) and T_2 weighted MR images (TR/TE 1800–3500/60–100 ms). Coronal and sagittal images were obtained in all cases. MR parameters were: 256 × 192 matrix, 14–18 cm field of view, two excitations, echo train length 8, 3 mm section thickness, 1 mm intersection gap.

The statistical differences between the presence and absence of the meniscomfemoral ligament as well as prevalence of lateral meniscal tear on MR images were evaluated by χ^2 tests. A p -value of less than 0.05 was regarded as statistically significant.

Results

Either one or both meniscomfemoral ligaments were identified on the MR images in 114 of 138 (83%) cases (Figure 1). The meniscomfemoral

Received 29 March 1999 and in final form 4 August 1999, accepted 25 August 1999.

Address correspondence to Won-Hee Jee, MD.

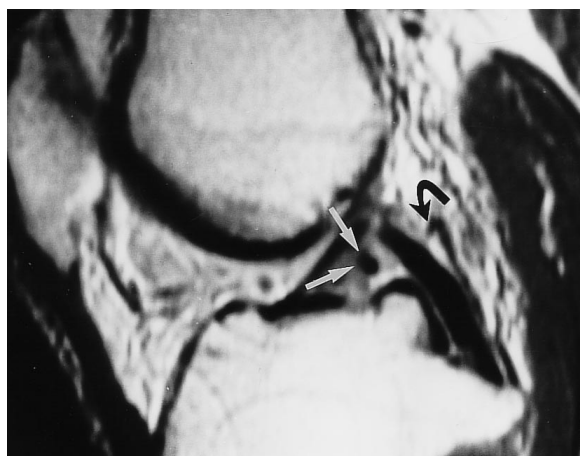ligament was visualized on coronal images in 107 of 138 (78%) cases, on sagittal images in 84 of 138 (61%) cases, while it was identified on coronal images alone in 30 of 138 (22%) cases (Figure 2) and on sagittal images alone in 7 of 138 (5%) cases. The ligament of Wrisberg was visualized on MR images in 110 of 138 (80%) patients (Figure 1), while the ligament of Humphrey was detected on MR images in 6 of 138 (4%) patients (Figure 1). The ligaments of both Wrisberg and Humphrey were identified in 2 (1%) cases (Figure 1).

The meniscofemoral ligament was present in 50 of 61 (82%) cases with lateral meniscal tears (Figures 1 and 2) and absent in 11 (18%) cases. The meniscofemoral ligament was present in 64 of 77 (83%) cases without lateral meniscal tears and absent in 13 (17%) cases. In 114 cases with a meniscofemoral ligament on MR images, lateral meniscal tears were present in 50 (44%) cases and absent in 64 (56%) cases. A similar ratio was obtained in the 24 cases where the meniscofemoral ligament was absent with lateral meniscus tears present in 11 (46%) and absent in 13 (54%) of cases. Six patients with a ligament of Humphrey on MR images showed three lateral meniscal tears and three medial meniscal tears. The detectability of the meniscofemoral ligament in patients with lateral meniscal tears was 82%, while the detectability in patients with medial meniscal tears was 83%. There was, therefore, no significant correlation between the presence of the meniscofemoral ligament and a lateral meniscal tear ($p > 0.85$).

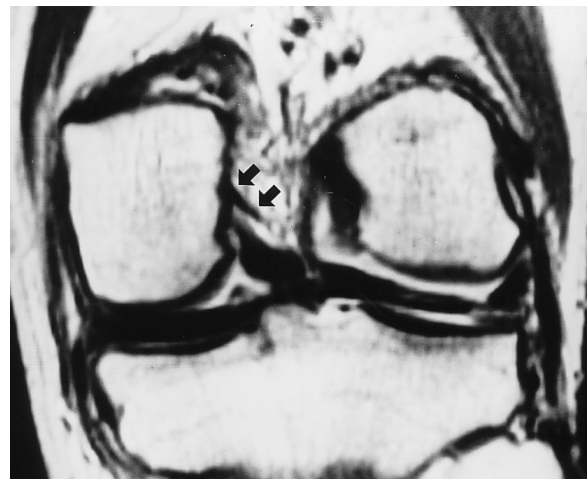Discussion

The meniscofemoral ligament is a strong collagen fibrous band in the knee. It arises from the lateral aspect of the medial condyle of the femur and passes distally and laterally to be inserted onto the posterior horn of the lateral meniscus. It may consist of one or two branches. The more constant is the ligament of Wrisberg, posterior to the posterior cruciate ligament. The anterior branch is the ligament of Humphrey, anterior to the posterior cruciate ligament [1].

In contrast to previous reports [2, 3], the meniscofemoral ligament was visualized on MRI in most (83%) cases in this study. Vahey et al [2] visualized the meniscofemoral ligament in 54 of 109 (50%) cases. Watanabe et al [3] concluded that either the ligament of Wrisberg or the ligament of Humphrey were identified in 124 of 200 (62%) cases and both ligaments were identified in 3% of the MR images. This discrepancy could be related to different MR parameters in each study. In those previous studies [2, 3], MR images were obtained with 5 mm section thicknesses and only sagittal MR images were evaluated. In our study, coronal and sagittal MRI was obtained with 3 mm section thicknesses and 1 mm intersection gap. The ligament of Humphrey was visualized in 4% of patients in our study, compared with 33% of patients in the study by Watanabe et al [3]. The cause for this difference is uncertain. We only identified the ligament of Humphrey when it was greater than 3 mm in size. Thus, we did not



(a)



(b)

Figure 1. Visualization of the meniscofemoral ligament on (a) sagittal and (b) coronal proton density weighted MR images in a 69-year-old man with a lateral meniscal tear. In (a) the ligament of Wrisberg (black curved arrow) and the ligament of Humphrey (white arrows) are identified as small, ovoid hypointense structures immediately posterior and anterior to the posterior cruciate ligament, respectively, on sagittal proton density weighted MR images. In (b) the ligament of Wrisberg is visualized as a hypointense band (arrows) on coronal proton density weighted MRI.

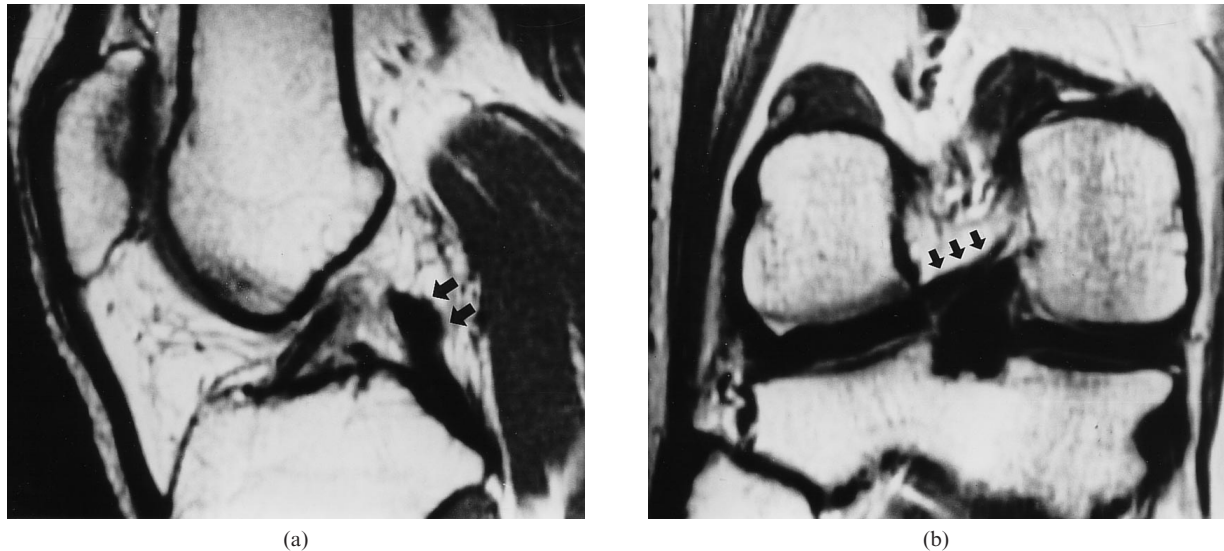


Figure 2. Visualization of the meniscofemoral ligament on (a) sagittal and (b) coronal proton density weighted MR images in a 40-year-old man with a lateral meniscal tear. In (a) the bulging (arrows) at the posterior aspect of the posterior cruciate ligament probably represents the ligament of Wrisberg but did not meet our criterion of being greater than 3 mm thick on the sagittal images alone. In (b) the ligament of Wrisberg (arrows) is identified as a thick hypointense band on coronal proton density weighted MRI.

include cases where the ligament of Humphrey was small or subtle. This strict criterion for the identification of the ligament of Humphrey may explain the lower rate of visualization than in the previous study.

Our results are consistent with previous anatomical studies [1, 5–9] which found either the anterior or posterior meniscofemoral ligament in 70–100% of knee joint specimens; the ligament of Wrisberg in 35–93% and the ligament of Humphrey in about 30%. In our study, however, the ligament of Wrisberg was visualized in 80% of cases, while the ligament of Humphrey was identified in only 4% on MR images. The discrepancy may be due to variable frequency and size of the ligament as well as our strict criterion (>3 mm) for recording the structure.

There are several limitations to this study. The minimum thickness for accepting a meniscofemoral ligament may have been too large and probably accounts for the reduced detection rate compared with other studies [5]. As the study is retrospective and all patients had either medial or lateral meniscal tears, there is an inherent selection bias. However, this was necessary for arthroscopic correlation.

The mobility of the posterior horn of the lateral meniscus is controlled by the meniscofemoral ligament as well as by the popliteus tendon. The posterior horn of the lateral meniscus usually has a double attachment. The anterior portion is attached to the tibial intercondylar eminence while, in the majority of cases, the posterior portion is inserted into the femur via the meniscofemoral ligament. During flexion of the knee with the foot fixed, the meniscofemoral

ligament pulls the posterior horn medially and slightly anteriorly, increasing the congruity between the meniscotibial socket and the lateral femoral condyle. The meniscofemoral ligament is a stabilizer for the posterior horn of the lateral meniscus. The lateral meniscus is therefore injured less often than the medial owing to this controlled mobility [10, 11]. We hypothesized that absence of the meniscofemoral ligament may increase the likelihood of tear of the posterior horn of the lateral meniscus. We found no significant correlation between the presence or absence of the meniscofemoral ligament and a lateral meniscal tear in our study.

Acknowledgments

The authors thank Thomas R McCauley, MD, for his invaluable review of the manuscript.

References

1. Brantigan OC, Voshell AF. Ligaments of the knee joint: the relationship of the ligament of Humphrey to the ligament of Wrisberg. *J Bone Joint Surg (Br)* 1945;25:66–7.
2. Vahey TN, Bennett HT, Arrington LE, Shelbourne KD, Ng J. MR imaging of the knee: pseudotear of the lateral meniscus caused by the meniscofemoral ligament. *AJR* 1990;154:1237–9.
3. Watanabe AT, Carter BC, Teitelbaum GP, Bradley WG. Common pitfalls in magnetic resonance imaging of the knee. *J Bone Joint Surg (Am)* 1989; 71:857–62.
4. Watanabe AT, Carter BC, Teitelbaum GP, Seeger LL, Bradley WG Jr. Normal variations in MR imaging of the knee: appearance and frequency. *AJR* 1989;153:341–4.

5. Cho JM, Suh JS, Na JB, Cho JH, Kim Y, Yoo WK, et al. Variations in meniscofemoral ligaments at anatomical study and MR imaging. *Skeletal Radiol* 1999;28:189–95.
6. Girgis FG, Marshall JL, Al Monajem ARS. The cruciate ligaments of the knee joint: anatomical, functional and experimental analysis. *Clin Orthopaed Rel Res* 1975;106:216–31.
7. Wan AC, Felle P. The menisco-femoral ligaments. *Clin Anat* 1995;8:323–6.
8. Yamamoto M, Hirohata K. Anatomical study on the menisco-femoral ligaments of the knee. *Kobe J Med Sci* 1991;37:209–26.
9. Heller L, Langman J. The meniscofemoral ligaments of the human knee. *J Bone Joint Surg* 1964; 46:307–13.
10. Last RJ. Some anatomical details of the knee joint. *J Bone Joint Surg (Br)* 1948;30:683–8.
11. Covey DC, Sapega AA. Anatomy and function of the posterior cruciate ligament. *Clinics Sports Med* 1994;13:509–18.